
CASE REPORT**Body Stalk Syndrome: A Curiosity***Anita Javalgi^{1*}, Anilkumar S.², Arakeri Surekha¹, Mamta K.¹**¹Department of Pathology, Shri B. M. Patil Medical College,**Bijapur - 586101 (Karnataka), India, ²Department of Pathology, Employees State Insurance Corporation (ESIC), Post Graduate Institute of Medical Sciences Research (PGIMSR), Sedam Road, Gulbarga - 585101 (Karnataka), India.***Abstract:**

Limb body wall complex (LBWC) /Body stalk syndrome anomaly refers to a rare complicated polymalformative fetal malformation syndrome of uncertain etiology firstly described by Van Allen *et al* in 1987. There are very few cases reported in literature and thus we report a rare case of LBWC. Twenty seven years female presented to labour room with 32 weeks of gestation with no prenatal care and delivered a low birth weight still born fetus weighing 1100gms. On fetal autopsy large abdominal wall defect was noted with difficulty in identifying abdomino-pelvic organs and ambiguous genitalia. Placenta weighed 250gms with attached short umbilical cord measuring 7cms, arising from periphery. A cyst noted attached to placental membrane measuring 9x5cms which on dissection retrieved partially maldeveloped organs. Post mortem radiological findings included Absence of right femur with short tibia and right fibula, Complex vestibral malformation, Craniosynostosis and Overcrowding of ribs.

Keywords: Abdominal Wall Defect, Second Trimester, Short Umbilical Cord

Introduction:

Limb body wall complex (LBWC) is a fetal malformative syndrome which starts early in the gestational process [1, 2]. It includes neural tube defects, body wall disruption and limb abnormalities [1-3]. The diagnosis is made by atleast two of the above features [1]. The incidence is 0.21 – 0.31/ 10000 deliveries and the prevalence has increased from approximately one in 14000 pregnancies to one in 7500 in recent studies [1, 4].

Russo *et al* proposed two clearly indistinguishable phenotype; placento-cranial and placento-abdominal phenotype [3].

Here we report a case of placenta-abdominal adhesion phenotype of limb body wall complex in 32 weeks of gestation.

Synonyms: Limb-body wall complex, body stalk anomaly, aplasia of the cord, cyllosomes [5].

Case Report:

Twenty seven years old female unbooked multi-gravida with P₂L₂A₁ with an uneventful antenatal period was referred to labour ward. There was no history of consanguinity or family history of malformation nor was there any history of drug intake during pregnancy. No antenatal USG was done.

At 32 weeks of gestation, she was admitted with preterm onset of labour and delivered a stillborn fetus. Post mortem x ray was taken (Fig. 1).

On autopsy there was malformed baby with ambiguous genitalia. On ischial tuberosity two skin tags and right limb mal rotation was noted. No anal opening was noted. Placenta was directly attached at left gluteal region and covering anterior abdominal wall. A cyst was noted measuring 9x6cm, enclosing the abdominal organs (Fig. 2).

On separation placenta weighed 250gms and umbilical cord arising from periphery measured 7cm in length. On cut section of cyst (Fig. 3),

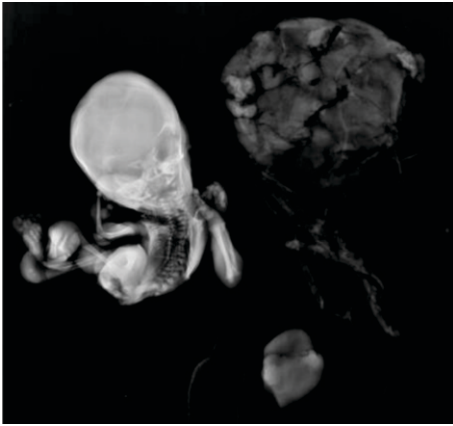


Fig. 1: Post-Mortem Radiographic Finding Shows Absence of Right Femur with Short Tibia and Right Fibula, Complex Vertebral Malformation, Craniosynostosis, Overcrowding of Ribs.

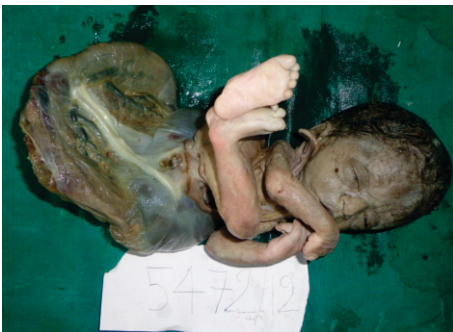

Fig. 2: Malformed Baby

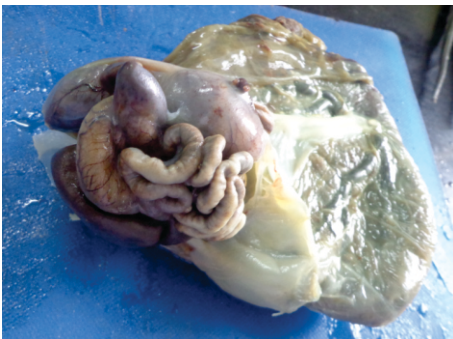

Fig. 3: Ruptured Cyst Showing Abdominal Organs

drained scanty serous fluid and retrieved abdominal organs were seen. Abdominal organs included mal developed small intestine and colon. Well developed liver, spleen, pancreas and heart were there in the cyst.

On Internal examination: Thoracic dissection- Only lungs and thymus were retrieved. Abdominopelvic dissection retrieved no organs

Microscopically bilateral lungs and intestine showed hypoplasia.

No specific pathology was noted in thymus, spleen, adrenal glands, heart and kidneys.

No genital organs could be identified microscopically. The umbilical cord showed a single artery. On postmortem X-ray and autopsy findings diagnosis of LBWC was confirmed.

Discussion:

LBCW is a rare anomaly appearing in 0.21 – 0.31/ 10000 deliveries, with only 245 cases described in the literature [6, 7]. Van Allen described the syndrome for the first time in 1987 and mentioned three essential features:

1. Exencephaly / encephalocele with facial clefts,
2. Thoraco and abdominoschisis
3. Limb defect.

In general, the diagnosis is based on 2 of the above features [1, 2]. Two main phenotypes have been described in the literature by (Russo *et al.* 1993) [2]

1. Fetuses with craniofacial defects (placentocranial)-whose characteristics are

- (a) Encephalocele or exencephaly always associated with facial clefts and
- (b) Amniotic bands between the cranial defects and placenta.

2. Fetuses without craniofacial defects (placento-abdominal)- they often presents with urogenital anomalies, anal atresia, lumbosacral meningocele and placental anomalies like presence of short cord, persistence of extra embryonic coelom and intact amnion [1-3].

Pathogenesis of LBWC is unclear and uncertain. However the proposed theories on the pathogenesis of the BWC include [1-3].

- (a) Germ disc defect with early embryonic maldevelopment (Streeter, 1930; Herva *et al.*, 1984; Bamforth, 1992),
- (b) Primary rupture of the amnion leading to the formation of amniotic bands (Torpin, 1965),
- (c) Vascular disruption (Van Allen, 1987) and
- (d) Disturbance of the embryonic folding process (Hartwig *et al.* 1989, 1991).

Body stalk syndrome is a theory of vascular disruption during the first 4 - 6 weeks of gestation. Other studies have shown that alternative causes of vascular disruption such as trauma, hypoxia and use of vasoconstrictive agents in early pregnancy can also lead to similar abnormalities. And no such pathological change was observed in the present case.

The most acceptable theory and compatible with the findings in this case, is that of a developmental anomaly. This theory was first proposed by Streeter in 1930. From the detailed examination of postmortem specimens he demonstrated bands of amniotic tissue that were continuous with, rather than adherent to, the defects in the fetus. His hypothesis was that these defects were the result of an abnormal folding of the embryo which caused maldevelopment of the amniotic cavity and the germ-disc [8].

In Van Allen *et al* [9] series of 25 cases, the amniotic membrane was continuous with the skin of the body wall defect in 85% which is consistent with the theory of developmental anomaly. Abnormal development at the trilaminar stage would also account for the common finding of a single umbilical artery, which is present in over 50% of cases as compared to the incidence in the general population of less than 1%.

LBWC must be differentiated from abdominal wall defects classified according to their localisation: gastroschisis, localized in the paraumbilical area, omphalocele, localized in the umbilical area, ectopia cordis localized at the anterior face of the thorax, cloacal dystrophy -localized at the lower abdominal wall, urachal cyst, localized also at the lower anterior abdominal wall [1].

There is no correlation with the fetal gender, parent's age, or karyotype anomalies, as in our study too. The disease is invariably fatal with no risk of recurrence [1, 3].

Pregnancy should be terminated once correct diagnosis is established which requires careful ultrasonographic examination of the fetus whenever ventral body wall defect with other malformations are suspected. Exomphalous requires chromosomal analysis (seen in trisomies 13, 18 & 21) and isolated gastroschisis is the most benign of all. Thus it is important to distinguish between these entities, as it will influence the choice of the treatment [3].

Conclusion:

LBWC is a rare fetal anomaly with specific signs like the presence of membranes covering the contents of the herniated sac, any associated bowel abnormalities, the presence or absence of urinary bladder, scoliosis and limb defects. Structural components of the syndrome, usually exencephaly, can be identified on second trimester ultrasound examination; however, the definitive diagnosis is usually not made until post-mortem examination. It is a fatal syndrome and hence early diagnosis and termination of pregnancy is required, with reassurance to parents of no recurrence for next pregnancies.

References:

1. Socolov D, Terinte C, Gorduza V, Socolov R, Puiu J M. Limb Body Wall Complex - case presentation and literature review. *Rom J Leg Med* 2009; 17(2): 133–138.
2. Plakkal N, John J, Jacob SE, Chithira J, Sampath S. Limb body wall complex in a still born fetus : a case report. *Cases J* 2008; 1: 86.
3. Saritha S, Supriya G, Kumar PM. Limb body wall complex- a case report. *International J of Biomed sciences* 2012; 5(3):1-8.
4. Luehr B, Lipsett J and Quinlivan J. Limb body wall complex – a case series and review of the literature. *Ultrasound Obstet Gynecol* 2001; 18: P103.
5. Umbilical cord, short umbilical cord syndrome. Catte LC, Waterschoot T, Mare C, Goossens A, Foulon W, [http: www.sonoworld.com](http://www.sonoworld.com) ; 1993-03-19-21.
6. Dens C, De Catte L. Limb-body wall complex: prenatal diagnosis of 15 cases. *Ultrasound Obstet Gynecol* 2003; 22(s1):83.
7. Smrcek JM, Germer U, Krokowski M, Berg C, Krapp M, Giepel A. Prenatal ultrasound diagnosis and management of body stalk anomaly: analysis of nine singleton and two multiple pregnancies. *Ultrasound Obstet Gynecol* 2003; 21:322-328.
8. Paul C, Zosmer N, Jurkovic D and Nicolaides K. A case of body stalk anomaly at 10 weeks of gestation. *Ultrasound Obstet Gynecol* 2001; 17:157–159.
9. Van Allen MI, Curry C, Gallagher L. Limb body wall complex: 1.pathogenesis. *Am J Med Genet* 1987; 28: 529–548

**Author for Correspondence: Dr. Anita P. Javalgi, Department of Pathology, Shri B. M. Patil Medical College, Bijapur - 586101, (Karnataka), India. Cell: 09739619068, Email: anitajawalgi@gmail.com*